



Hydrosalpinx in dairy goats: Occurrence, ultrasound diagnosis, macro- and microscopic characterization

A.L.R.S. Maia^{a,*}, F.Z. Brandão^a, J.M.G. Souza-Fabjan^{a,b}, M.C.C. Araújo^c, L.G.B. Siqueira^d, O. Facó^e, J.F. Fonseca^e

^a Universidade Federal Fluminense, Av. Vital Brazil Filho, 64, CEP 24230-340, Niterói, RJ, Brazil

^b Escola de Ciências da Saúde, Universidade do Grande Rio, Rua Prof. José de Souza Herdy, 1160, CEP 25071-202, Duque de Caxias, RJ, Brazil

^c Departamento de Morfologia e Histologia, Instituto de Ciências Biológicas, Universidade Federal de Juiz de Fora, Rua José Lourenço Kelmer, s/n, CEP 36036-900, Juiz de Fora, MG, Brazil

^d Embrapa Gado de Leite, Av. Eugênio do Nascimento, 610, CEP 36038-330, Juiz de Fora, MG, Brazil

^e Embrapa Caprinos e Ovinos, Estrada Sobral/Groaíras, km 04, CP 145, CEP 62010-970, Sobral, CE, Brazil

ARTICLE INFO

Keywords:

Caprine
Differential diagnosis
Histopathology
Infertility
Oviduct disease
Subfertility

ABSTRACT

Hydrosalpinx is an oviduct disease that can compromise female fertility. This study describes the occurrence and characterization of hydrosalpinx in dairy goats and proposes a new approach for an accurate diagnosis of hydrosalpinx by using transrectal ultrasonography (US). The data were collected from 2579 goats subjected to US exams. Six goats had their reproductive tracts collected *post mortem* and macroscopically and microscopically examined. A total of 28 cases of hydrosalpinx (1.1%) were detected: 27 Saanen goats and one Alpine goat. Among these, 22.2% (6/27) had previously shown other reproductive disorders such as spontaneous abortion (3.7%), follicular cysts (3.7%) and hydrometra (14.8%). Only the oldest goat (12 years old) was pluriparous with history of previous reproductive success, while 27 nulliparous females ranged in age from one to eight years old. The US exams revealed a fluid-filled, rounded structure (> 24 mm) formed by the accumulation of fluid inside the oviduct lumen of the affected goats. The infundibulum was the most commonly affected region, and contained rounded structures up to 100 mm in diameter. The ampulla was the second most commonly affected structure, and minor changes were observed in the isthmus. In one of the 28 positive cases, the presence of bilateral hydrosalpinx was identified. Microscopically, at the infundibulum and ampulla, a decrease and/or absence of the mucosal folds with subsequent reduction of the epithelial surface area was noted. In conclusion, hydrosalpinx may be successfully diagnosed in goats via transrectal US. The occurrence rate of hydrosalpinx in this study reveals the importance of an accurate diagnosis and a strong possibility that hydrosalpinx has been underdiagnosed and neglected in this species.

1. Introduction

Brazil has more than nine million goats spread over different regions of the country. Approximately five million of these goats are raised for milk production (FAOSTAT, 2014). Increasing productivity is still essential for greater profitability and competitiveness of dairy goat milk production. In cattle, the incidence of reproductive disorders, advanced age at first calving and extended calving intervals are among the most important limiting factors for the expansion of livestock production (De Kruif, 1978). Studies carried out with slaughterhouse animals have identified diverse causative factors of subfertility or infertility in small ruminants, including abnormalities of the ovary, oviduct or uterus (Sattar et al., 1988; Santa Rosa, 1996; Palmieri et al., 2011).

Hydrosalpinx is an oviduct disease that can partially or fully compromise female fertility, depending upon whether the disease occurs unilaterally or bilaterally (Noakes et al., 2001; Purohit, 2014). Hydrosalpinx is characterized by a dilated lumen in any of the three portions of the oviduct and may affect up to 80% of the organ (Santa Rosa, 1996). The possible causes of hydrosalpinx include congenital malformations or an inflammatory process sequela (Grunert et al., 2005). Despite its detrimental effect on fertility, hydrosalpinx is generally identified only after slaughter, and some studies have addressed the occurrence of hydrosalpinx in goats found at slaughter (Sattar et al., 1988; Beena et al., 2015). However, the use of transrectal ultrasonography (US) allows the identification of changes or abnormalities in the female reproductive tract in a noninvasive, real-time manner,

* Corresponding author.

E-mail address: maia.analucia@gmail.com (A.L.R.S. Maia).

which provides immediate clinical answers (Medan and Abd El-Aty, 2010). The US examination of the reproductive tract of females with a history of infertility that reveals anechoic content in segments cranial to the urinary bladder may often lead to the diagnosis of hydrometra or cystic ovarian disease (Janett et al., 2001; Dawood, 2010). These ultrasonographic findings may be confounding factors that could hamper the correct diagnosis of hydrosalpinx. Currently, there is only one report in the literature describing the occurrence of hydrosalpinx in one live goat. Interestingly, the animal was previously treated for hydrometra. The laparoscopic procedure resulted in the correct diagnosis of hydrosalpinx (Janett et al., 2001).

Therefore, the objective of this study was to present the ultrasonographic diagnosis of hydrosalpinx in goats and to describe its macro- and microscopic characteristics. Additionally, a new approach for an accurate differential diagnosis of hydrosalpinx and other reproductive pathological conditions was proposed.

2. Materials and methods

2.1. Ethics and animal care

The Animal Care Committee of the Universidade Federal Fluminense approved the study design (protocol number #678/2015), and the experiment was conducted under the principles of the Brazilian Society of Laboratory Animal Science.

2.2. Location and study conditions

Data were collected between January 2015 and March 2017 from dairy goats of 22 commercial herds located in the Southeastern region of Brazil (States of São Paulo, Rio de Janeiro, Espírito Santo and Minas Gerais). In 19 farms, goats were raised in an intensive production system, confined in group pens, fed with chopped *Pennisetum purpureum* forage or corn silage and concentrate supplementation. In the three remaining farms, the production system was semi-intensive with access to pasture. Water and mineralized salt (Caprinofós[®]; Tortuga, São Paulo, Brazil) were available *ad libitum*.

2.3. Animals

Dairy breed goats (n = 2579) ranging from eight months to 12 years of age were subjected to transrectal ultrasonographic examination. The majority of the enrolled goats were Saanen (77.4%; 1996 of 2579), but other breeds included Alpine (14.0%; 361 of 2579), Toggenburg (6.7%; 172 of 2579), Anglo-Nubian (0.3%; 8 of 2579) and crossbreeds (1.6%; 42 of 2579).

2.4. Ultrasonography

The reproductive tract of each goat was examined by a single operator using a B-mode, transrectal ultrasonographic scanner (Mindray[®]; M5Vet, Shenzhen, China), equipped with a linear 5.0 MHz transducer taped to a PVC tube to facilitate its use in small ruminants (Souza et al., 2013). During US evaluations, goats remained standing, restrained by an assistant. To prevent the spread of pathogens among the female goats, plastic sanitary sleeves developed to fit the US rectal transducer (Camisinha para probe retal[®]; NTB Indústria e Comércio de Produtos para Pecuária LTDA, São Paulo, Brazil) were used, with a new sleeve being applied to the US rectal transducer after each examination. A syringe containing 10 mL of carboxymethylcellulose gel (Carbogel UTL[®]; Carbogel Indústria e Comércio LTDA, São Paulo, Brazil) was used to deposit lube into the goat's rectum for lubrication and to increase the contact surface between the transducer and the wall of the rectum.

After visualization of the urinary bladder, imaging of the uterus and ovaries were performed to evaluate reproductive soundness. Once an abnormality was observed on the reproductive organs, sonographic

representative images were saved for subsequent analysis. In cases of recent mating (< 30 days), positive pregnancy diagnoses were re-confirmed at a later stage of gestation (60 days). Females diagnosed with hydrometra and mucometra were treated as previously described (Maia et al., 2016) and re-evaluated by US 30 days later to confirm whether the uterine contents were expelled. Thus, during the study period, some females were examined by US more than once.

2.5. Macroscopic and microscopic analysis

Six goats presenting with histories of infertility and with US evaluations suggestive of hydrosalpinx were discarded by producers, and their reproductive tracts were recovered in the slaughterhouse. The tracts of four of these six goats were macroscopically examined, measured and photographed with a DSLR digital camera (Canon EOS Rebel XSi[®]; Tokyo, Japan), and the reproductive tracts were microscopically analyzed, as described below.

Tissue fragments of the three anatomical portions of the oviduct (infundibulum, ampulla, isthmus) and from both uterine horns were collected from two goats, which had no apparent abnormalities other than hydrosalpinx. The 2-cm³ tissue fragments were fixed in a solution of 10% formaldehyde buffered with sodium phosphate 0.1 M at 4 °C for 24–48 h. After fixation, a standard histological procedure (dehydration, diaphanization and inclusion in paraffin) followed by microtomy cuts with a thickness of 4 µm was performed after a 20-µm thinning of the specimen. The histology sections were mounted and stained with hematoxylin and eosin (H&E). The microscopic evaluations of tissue samples were performed using an optical microscope (Primo Star LED[®]; Carl Zeiss Microscopy GmbH, Göttingen, Germany) attached to a digital camera (Axio Cam ERc 5s[®]; Carl Zeiss Microscopy GmbH, Göttingen, Germany). Images were captured and analyzed using an image processing software (ZEN lite 2012[®]; Carl Zeiss Microscopy GmbH, Göttingen, Germany). Assessment of morphometric features was performed in six fields of each fragment by examining the epithelium, connective tissue and muscular layers (Wittek et al., 1998; Zhu et al., 2013).

2.6. Statistics

Data are presented in a descriptive form. The determined end points were overall hydrosalpinx occurrence rate, hydrosalpinx occurrence rate per breed, hydrosalpinx occurrence rate per category (either nulliparous or pluriparous) and hydrosalpinx occurrence rate associated with other reproductive disorders.

3. Results

3.1. Hydrosalpinx occurrence

Of the 2579 goats examined by ultrasonography, 28 cases of hydrosalpinx (1.1%) were detected. Twenty-seven of the goats with hydrosalpinx were Saanen (1.35%; 27/1996) and one was Alpine (0.27%; 1/361). Only the oldest goat (12 years old) was pluriparous with history of previous reproductive success. The majority of other 27 nulliparous females were between one and two years of age (23/27; 85.2%), with an overall age range of one to eight years old.

Anamnesis revealed that all the nulliparous goats had shown previous estrus, had been mated by fertile bucks, but never had successful pregnancies and therefore no history of kidding. Among these goats, 22.2% (6/27) had previously shown other reproductive disorders, either reported by the farmer [spontaneous abortion, (3.7%; 1/27)] or diagnosed via US in the present study [follicular cyst (3.7%; 1/27) and hydrometra (14.8%; 4/27)]. In the four goats diagnosed with hydrometra, visualization of oviductal alterations was only possible after treatment and complete emptiness of uterine content.

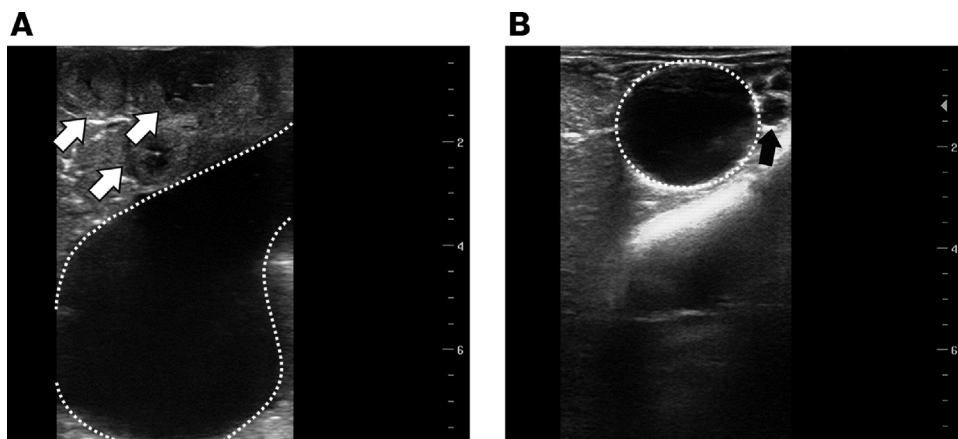


Fig. 1. Ultrasound images characteristic of hydro-salpinx, which is characterized as a rounded, anechoic structure (dashed line), formed by the accumulation of fluid in the lumen, positioned: (A) lateral to transverse cuts of the uterine horn (white arrow) showing normal echogenicity and morphology; (B) next to the ovary containing several follicles (black arrow).

3.2. Ultrasound exams

In females affected by hydrosalpinx, ultrasonographic examinations revealed the presence of a fluid-filled, rounded structure formed by the accumulation of fluid inside the oviduct lumen. These rounded structures were at least 24 mm in diameter. Thus, the characteristic US imaging pattern of hydrosalpinx was a rounded anechoic structure, in a position lateral to the uterine horn and the ovary (Fig. 1). The uterus had normal echogenicity and contours. In one of the 28 positive-cases, the presence of bilateral hydrosalpinx was identified, i.e., two rounded structures approximately 25 mm in diameter, one in each oviduct (left and right).

All US diagnoses were compared with the female's reproductive history to confirm sub-fertility or infertility. Additionally, we compared the differential diagnosis of hydrosalpinx with hydrometra and follicular cyst, as shown in Fig. 2. These three diseases could be confused due to similar patterns of anechoic structures.

3.3. Macroscopic analysis

Gross examination of the reproductive tract indicated oviductal distension due to the presence of a clear, watery fluid throughout the entire length of the organ (three anatomical regions). The infundibulum was the most commonly affected region, and contained rounded structures up to 100 mm in diameter. The ampulla was the second most commonly affected region, and minor changes were observed in the isthmus. In all goats, adhesions between the rounded structures and the ovaries were observed. In one goat, a narrowed portion of the oviduct followed the rounded structure, with the narrowed oviduct measuring 12 mm in diameter (Fig. 3A). The oviduct ended abruptly due to the absence of one of its segments (Fig. 3B and C).

Images of the changes observed during the *ante mortem* US examination, and the respective *post mortem* reproductive tracts are shown in Fig. 4. Three cases of bilateral hydrosalpinx and one case of unilateral hydrosalpinx were observed after slaughter.

3.4. Microscopic analysis

Histological specimens were evaluated for changes on the uterine horns and oviducts, and similar findings were detected in both organs. In the uterine samples, vacuolation and basophilia at the endometrial glands cells (Fig. 5A and B) and a flattening of the endometrial epithelium (Fig. 5C and D) were observed. At the infundibulum and ampulla, a decrease and/or absence of the mucosal folds (Fig. 6A, B and C) with subsequent reduction of the epithelial surface area was verified. At the infundibulum, a high rate of nuclear extrusion was observed in epithelial cells (Fig. 6D).

4. Discussion

The hydrosalpinx incidence rate of 1.1% of goats observed in this study was higher than previous reports of 0.02% (Sattar et al., 1988) and 0.3% (Beena et al., 2015) in studies that examined reproductive tracts at goat slaughterhouses. This relatively high occurrence of hydrosalpinx reveals the importance of its accurate diagnosis, as the disease considerably affects the fertility of dairy goats. Bilateral hydrosalpinx certainly leads to infertility because of the distension of several parts of the oviduct leading to compromised reproductive function. This demonstrates the potential for using transrectal US for the diagnosis of hydrosalpinx for species in which transrectal palpation cannot be performed. In the present study, hydrosalpinx was diagnosed mainly in nulliparous goats that were previously bred. Our group has recently

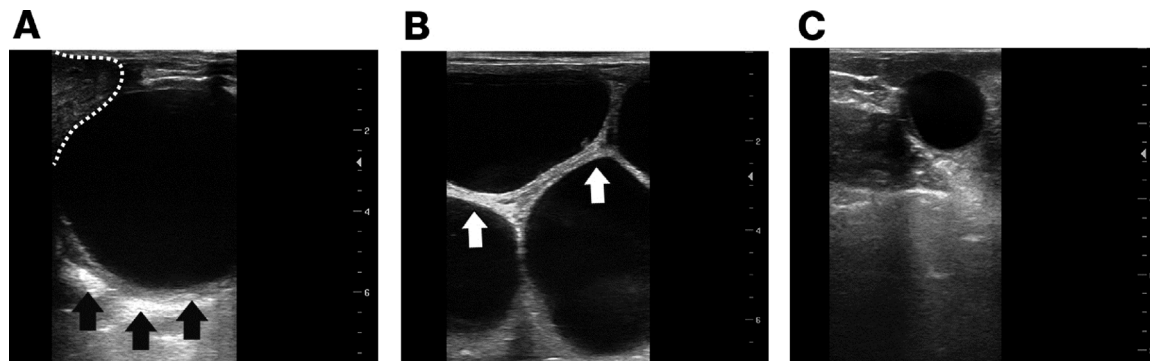


Fig. 2. The comparison of ultrasonographic images of the reproductive tract of goats. (A) anechoic, rounded structure characteristic of hydrosalpinx (next to uterus marked by dashed line) with acoustic reinforcement (hyperechoic region – black arrows) on the bottom of the structure; (B) severe hydrometra containing large anechoic segments, within the uterine lumen, surrounded by the hyperechoic uterine wall (white arrows); (C) ovarian follicular cyst.

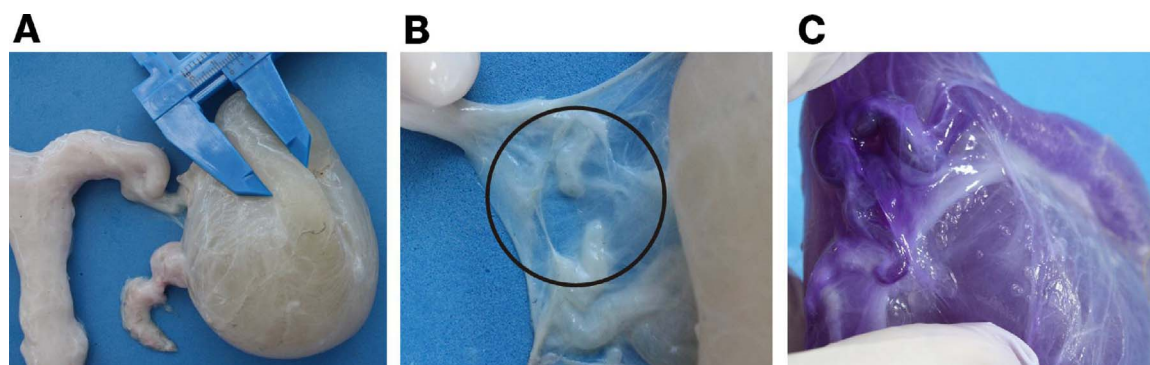


Fig. 3. (A) hydrosalpinx in a two-year old Saanen goat, characterized by the presence of a rounded structure followed by a narrowed portion of the oviduct, 12 mm in diameter; (B) confirmation of a segmental aplasia of the oviduct (center of the black circle); (C) confirmation after the infusion of gentian violet stain with a syringe and a 26 G needle of from the infundibulum towards the isthmus. (For interpretation of the references to colour in this figure legend, the reader is referred to the web version of this article.)

reported that Saanen nulliparous goats (younger than three years old) were ultrasonographic diagnosed more frequently with hydrosalpinx than other breeds (Alpine and Toggenburg) ($P < 0.05$) (Maia et al., 2017). In the reproductive management, repeat-breeders should be identified early during their first or their second breeding season at the latest. Interestingly, repeat-breeders are kept by the farmer in the herd due to their superior size and sturdy appearance. In fact, the latter characteristics may be a sign of reproductive failure if other herdmates of the same age are already pregnant or lactating. This fact reinforces the need for a routine ultrasound examination of all eligible females before the onset of the breeding season or estrus induction program and for pregnancy diagnosis approximately 30–60 days after breeding. Thus, transrectal US can be a tool for diagnosing the underlying cause of repeat breeding.

In order to have a correct US diagnosis, attention should be paid to the organs affected by hydrosalpinx (oviduct), hydrometra (uterus) and follicular cysts (ovaries). During the US exam, the uterus must be fully evaluated by checking the presence or not of liquid and/or concept and their appearance. After the examination of the uterus, the evaluation should be made on the ovaries for verification of follicles, corpus luteum and possible cysts. The oviduct is a paired, thin and tortuous organ that originates adjacent to the ovaries and extends to the tip of the uterine horns. This organ is only visible during current US examinations if it has pathological alterations. It is worth mentioning that it is not possible to identify by US examination the cause that lead to this alteration, as shown in *post mortem* evaluation (Fig. 3B). Usually, goats with a history of infertility and anechoic content noted on the US exams of the reproductive tract are often diagnosed with hydrometra or cystic ovarian disease (Janett et al., 2001; Dawood, 2010; Souza et al., 2013). These diseases may have characteristics that are confounding factors, which may hamper the correct diagnosis, as described by Janett et al. (2001). The confounding diagnosis of hydrosalpinx, hydrometra and follicular cyst by US occurs due to the presence of either large or small anechoic rounded structures. In case of doubt, US should be repeated after treatment with PGF2 α (hydrometra) or GnRH (follicular cyst). As reported in the present study, it is possible that hydrosalpinx occurs concomitantly to hydrometra. In this special case, a uterine emptying must be done in order to be possible to visualize the oviduct alteration. Another relevant factor that should be considered is that both hydrometra and follicular cyst have treatment, different from hydrosalpinx.

Interestingly, the US imaging of hydrosalpinx allows for visualization of sections of the uterine horn that have standard echogenicity aspect, which is different from the US imaging of hydrometra. Thus, US imaging of hydrosalpinx provides evidence of the absence of fluid in the uterine lumen. In early cases of hydrometra, several anechoic segments are observed, similar to a positive pregnancy diagnosis, but no fetus and/or embryonic vesicle are detected. In advanced cases, the uterine

wall divides numerous fluid-filled compartments, which have a hyperechoic imaging pattern (Pieterse and Taverne, 1986). Although hydrosalpinx may be characterized by a rounded structure with edges that have greater or lesser acoustic reinforcement of hyperechoic aspect, the major difference is that only one rounded structure is observed. Thus, transrectal US is an accurate method to differentiate between uterine pathology and oviduct abnormalities.

In the present study, US imaging revealed rounded structures, with a minimum diameter of 24 mm, formed by the accumulation of fluid at the anatomical region of the oviducts. Hydrosalpinx can also be confused with follicular cysts, leading to misdiagnosis. Medan et al. (2004) considered the existence of follicular cyst in goats when an anechoic structure > 10 mm was detected in the absence of a corpus luteum and the structure remained visible for a period of 15 days. In their study, the mean diameter of the cysts was 12.6 ± 0.4 mm. Apparently, ovarian cysts can reach up to 20 (Simões et al., 2009) or 30 mm (Gonzalez-Bulnes et al., 2010) in diameter, either in the presence of luteinization (luteal cyst) or not (follicular cyst). In the present study, the smaller, rounded structures had similar sizes compared to the sizes of ovarian cysts. One strategy to differentiate the pathologies could be the administration of GnRH, followed by PGF2 α 10 days later. Goats showing the ovarian disorder usually respond to treatment, and the cyst is not detected in future US assessments (Medan et al., 2004), which is different from hydrosalpinx. Our study determined the occurrence of hydrosalpinx based on the US visualization of rounded structures measuring approximately 24 mm and required a second US exam within a 10-day interval to confirm the diagnosis or response to treatment. In addition to the treatment attempt, the female reproductive history should be assessed before a final culling decision.

In the present study, we observed a concomitant occurrence of hydrometra and hydrosalpinx. In four goats (14.3%; 4/28), an initial diagnosis of hydrometra was followed by the observation of hydrosalpinx after the uterine content was expelled. Known causes of hydrometra include early embryonic loss, fetal death and abortion (Humboldt et al., 1995; Wittek et al., 1998; Souza et al., 2013) followed by luteolysis failure and, consequently, a permanent, functional corpus luteum. Alternatively, in some cases, hydrosalpinx may be the causative factor of embryonic/fetal loss and not its consequence. Earlier studies in mice suggested that fluid from the oviduct affected by hydrosalpinx could be toxic to the embryo *in vitro*, leading to impaired development; but this hypothesis was not further validated *in vivo* in humans (Revised by Strandell, 2000). Thus, the possibility of a relationship between embryonic/fetal loss and hydrosalpinx should not be ruled out.

In the *post mortem* macroscopic evaluation, it was noted an abrupt end of the oviduct due to the absence of one of its segments (Fig. 3B). According to Grunert et al. (2005), segmental aplasia of the oviduct occurs due to a malformation determined by congenital failure of the fetal development. This malformation can lead to hydrosalpinx. In

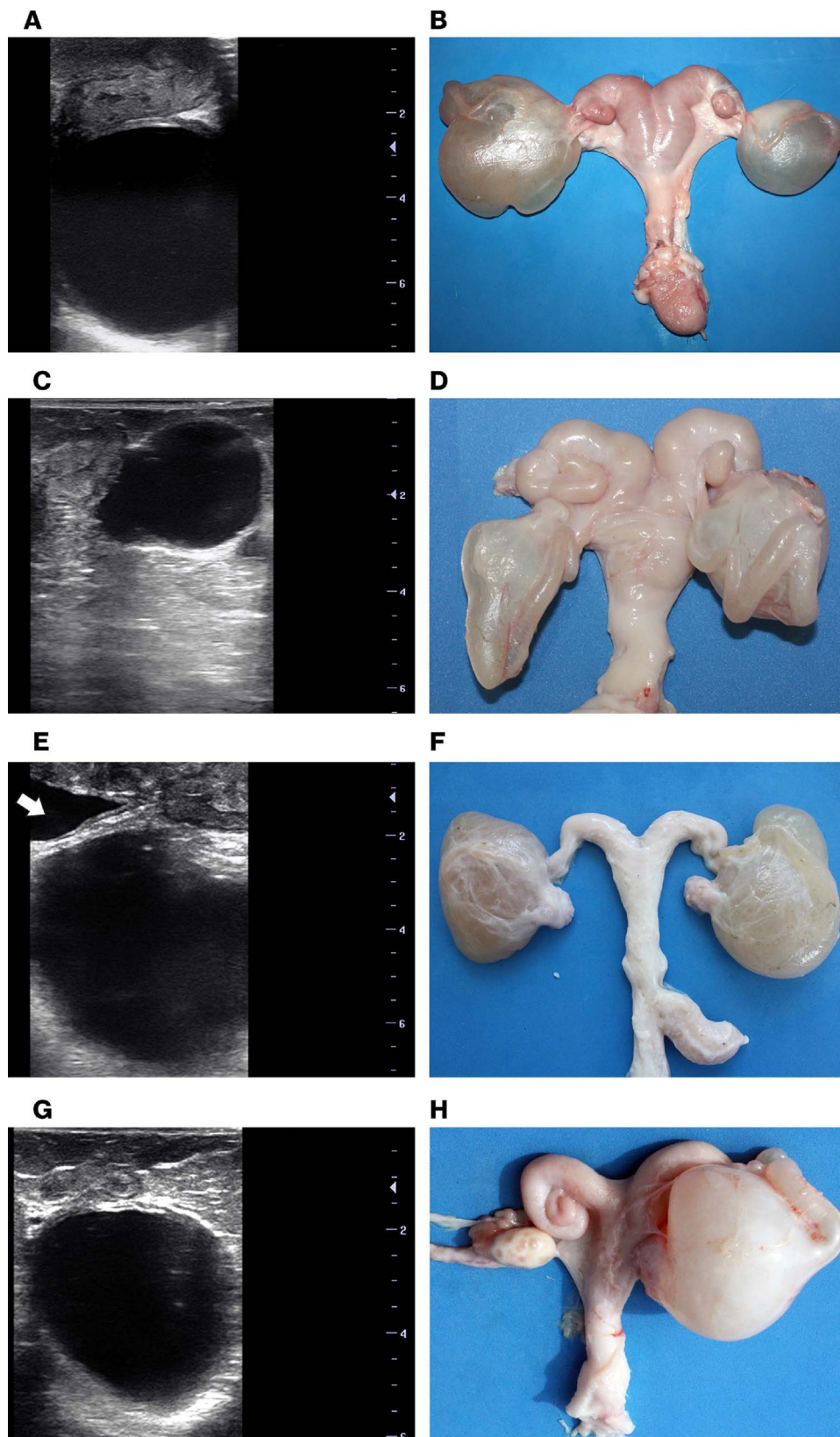


Fig. 4. Transrectal ultrasonographic images and gross appearance of the reproductive tracts of Saanen nulliparous goats affected by hydrosalpinx: (A) anechoic, rounded structure immediately below the uterine horn in a three-year-old goat; (B) the respective reproductive tract with bilateral hydrosalpinx showing rounded structures of 100 and 70 mm diameter on the left and right oviducts, respectively; (C) rounded-to-oval shaped structure, lateral to the uterine horn in a two-year-old goat; (D) the respective reproductive tract with bilateral hydrosalpinx with rounded structures of 24 and 35 mm in diameter on the left and right oviducts, respectively; (E) anechoic, rounded structure below the urinary bladder (indicated by an arrow) and the left uterine horn in a two-year-old goat; (F) the respective reproductive tract with bilateral hydrosalpinx showing rounded structures of 60 and 85 mm in diameter on the left and right oviducts, respectively; (G) rounded-to-oval, anechoic, structure below the uterine horn in a two-year-old goat; (H) the respective reproductive tract of unilateral right hydrosalpinx with a rounded structure of 55 mm in diameter and firm wall.

cows, when the aplasia is unilateral it can be related to the occurrence of repeat breeding. Our histological analyses indicated vacuolation of the endometrial gland cells and a flattening of the endometrial epithelium in samples from uterine horns. Similar alterations were observed by [Wittek et al. \(1998\)](#) in the endometrium of goats affected by

hydrometra. The presence of vacuoles in the cytoplasm is a characteristic of progesterone influence, which is a result of a persistent CL in cases of hydrometra and may indicate the phase of the estrus cycle in cases of hydrosalpinx. In samples from the oviduct infundibulum and ampulla, we observed a reduction in the epithelial surface as a

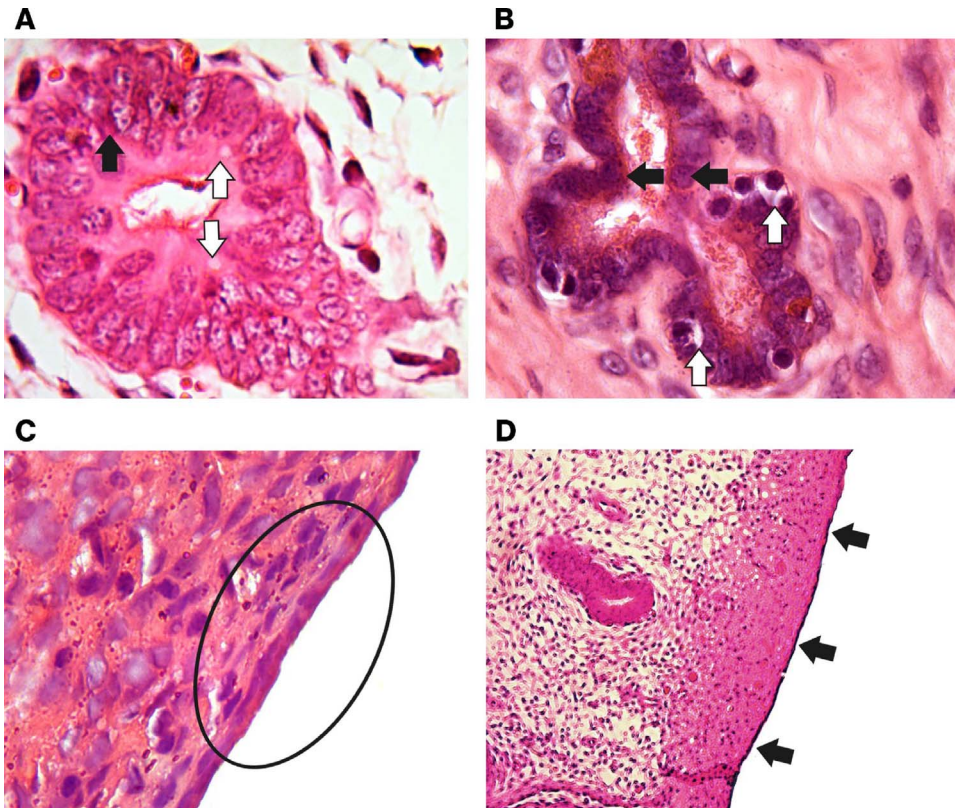


Fig. 5. Photomicrography of the uterine horn of a two-year-old Saanen nulliparous goat affected by hydrosalpinx: (A) left uterine horn showing vacuolation of the endometrial glands cells (white arrows) and basophilia (black arrow); hematoxylin-eosin stain (H&E), magnification x 100; (B) right uterine horn showing vacuolation of the endometrial gland cells (white arrows) and basophilia (black arrows) H &E, magnification x 100. (C) left horn with flattening of the endometrial epithelium (black circle), H&E, magnification x 40. (D) left horn with flattened endometrial epithelium (black arrows), H&E, magnification x 10.

consequence of absent mucosa folding. Santa Rosa (1996) has also observed mucosal atrophy characterized by a reduction of lining epithelial cells and the absence of folds in goats affected by hydrosalpinx. Similar features were observed by Rechsteiner et al. (2015) in mares.

These morphological changes probably occur due to the presence of an abnormal amount of fluid that generates pressure and distention of the oviduct lumen, leading to epithelial deformation. Not only the liquid increase in the organ but also the period of liquid accumulation is

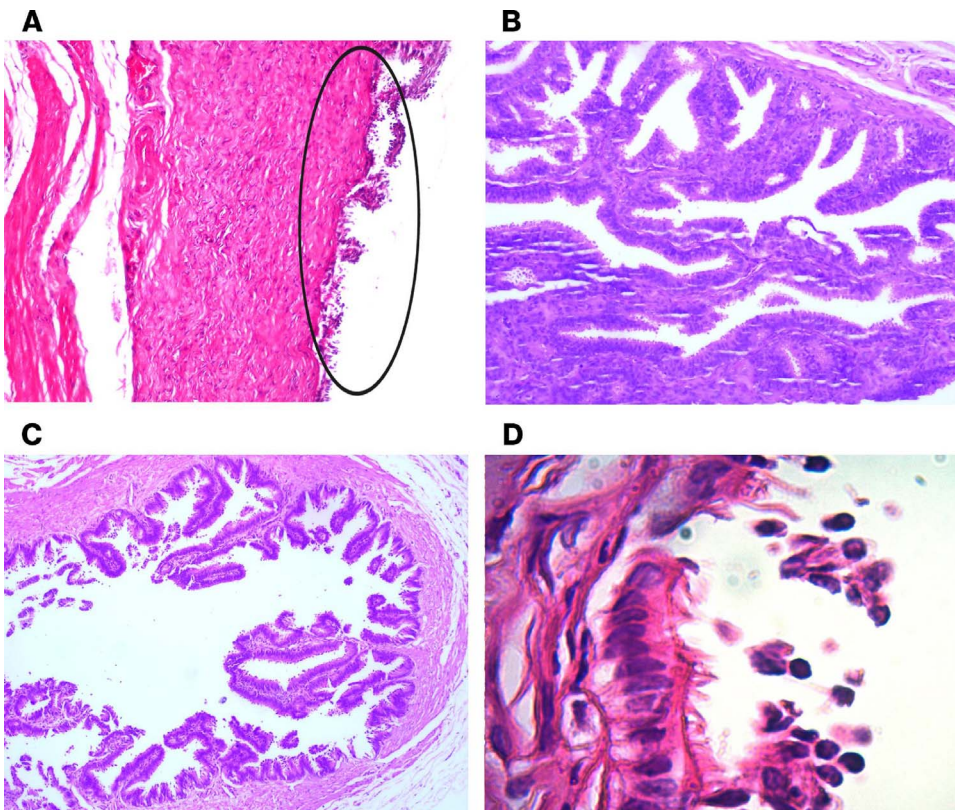


Fig. 6. Photomicrograph of the infundibulum and ampulla of a two-year-old nulliparous Saanen goat affected by hydrosalpinx: (A) right ampulla epithelium with loss of mucosal folds (circle), H&E, magnification x 4; (B) left infundibulum epithelium with similar loss of mucosal folds, H&E, magnification x 10; (C) reduction of mucosal folds at the left ampulla, H&E, magnification x 10. (D) nuclear extrusion of epithelial cells at the right infundibulum, H&E, magnification x 100.

important to the eventual morphological alterations. This abnormal condition leads to major changes in the oviduct histological characteristics and may cause loss of functionality.

5. Conclusions

This study demonstrates that hydrosalpinx may be successfully diagnosed in goats by transrectal US after differentiating the diagnosis from other conditions, such as hydrometra and follicular cysts. The relatively high occurrence of hydrosalpinx reported in the present study reveals the importance of the accurate diagnosis of the disease. Hydrosalpinx, as indicated by the results of this study, may be an important cause of reproductive failure in nulliparous goats that may stay in the herd for two years or more without producing offspring and milk.

Conflict of interest statement

There are no conflicts of interest regarding authorship or publication of this article.

Acknowledgments

This study was supported by the National Council for Scientific and Technological Development (CNPq Project nb 479826/2013-7), FAPEMIG (Foundation for Research Support of the State of Minas Gerais) (Project nb CVZ-PPM 00201-17) and EMBRAPA (Brazilian Agricultural Research Corporation) (Project nb 02.08.02.005.00.04). The authors also thank all the farmers involved, including CAPRIMA (Associação de Criadores de Cabras Leiteiras da Zona da Mata – MG) and CapraGene® associated herds for providing animals and animal housing conditions. FZB is a fellow of the CNPq and JMGSF of CAPES.

References

- Beena, V., Pawaiya, R.V.S., Shivasharanappa, N., Gururaj, K., Gupta, V.K., Gangwar, N.K., Singh, D.D., Karikalan, M., Sharma, A.K., Kumar, H., Kumar, A., Singh, R., 2015. Occurrence of pathological conditions in the female genitalia of goats. *Indian J. Vet. Pathol.* 39, 197–201.
- Dawood, K.E., 2010. Hydrosalpinx and hydrobursitis in infertile goats. *Turk. J. Vet. Anim. Sci.* 34, 477–480.
- De Kruif, A., 1978. Factors influencing the fertility of a cattle population. *J. Reprod. Fertil.* 54, 507–518.
- FAOSTAT, 2014. <http://www.fao.org/faostat/en/#data/QL>.
- Gonzalez-Bulnes, A., Pallares, P., Vazquez, M.I., 2010. Ultrasonographic imaging in small ruminant reproduction. *Reprod. Domest. Anim.* 45, 9–20.
- Grunert, E., Birgel, E.H., Vale, W.G., 2005. *Patologia e Clínica da Reprodução dos Animais Mamíferos Domésticos: ginecologia, primeira ed.* [Reproductive Pathology and Clinics of Domestic Mammals: gynecology first ed]. (Varela, São Paulo).
- Humblot, P., Brice, G., Chemineau, P., Broqua, B., 1995. Mortalité embryonnaire chez la chèvre laitière après synchronisation des chaleurs et insémination artificielle à contre saison. In: *Rencontres Recherches Ruminants, 2., 1995, Paris. Proceedings...* Paris. Institute National de la Recherche Agonomique – INRA. pp. 387–389.
- Janett, F., Lischer, C., Grest, P., 2001. Hydrosalpinx bei der ziege. *Schweizer Archiv. Tierheilk.* 143 (2), 105–108 (Abstract in English).
- Maia, A.L.R.S., Brandão, F.Z., Balaro, M.F.A., Santos, G.B., Souza-Fabjan, J.M.G., Facó, O., Fonseca, J.F., 2016. Monitoring of uterine contents reduction and reproductive restore during breeding season in goats affected by Hydrometra. In: *International Congress of Animal Reproduction, 18., 2016. Tours. Abstracts...* Tours: ICAR. pp. 378–379 (Abstract PW1026).
- Maia, A.L.R.S., Brandão, F.Z., Souza-Fabjan, J.M.G., Veiga, M.O., Balaro, M.F.A., Facó, O., Fonseca, J.F., 2017. Transrectal ultrasound evaluation in tropical dairy goats: an indispensable tool for the diagnosis of reproductive disorders. *Trop. Anim. Health Prod.* <http://dx.doi.org/10.1007/s11250-017-1496-0>.
- Medan, M.S., Abd El-Aty, A.M., 2010. Advances in ultrasonography and its applications in domestic ruminants and other farm animals reproduction. *J. Adv. Res.* 1, 123–128.
- Medan, M.S., Watanabe, G., Sasaki, K., Taya, K., 2004. Transrectal ultrasonic diagnosis of ovarian follicular cysts in goats and treatment with GnRH. *Domest. Anim. Endocrinol.* 27, 115–124.
- Noakes, D.E., England, G., Parkinson, T.J., Arthur, G.H., 2001. *Arthur's Veterinary Reproduction and Obstetrics*, eighth ed. Saunders Ltda, Philadelphia.
- Palmieri, C., Schiavi, E., Della Salda, L., 2011. Congenital and acquired pathology of ovary and tubular genital organs in ewes: a review. *Theriogenology* 75, 393–410.
- Pieterse, M.C., Taverne, M.A.M., 1986. Hydrometra in goats: diagnosis with real-time ultrasound and treatment with prostaglandins or oxytocin. *Theriogenology* 26, 813–821.
- Purohit, G.N., 2014. Ovarian and oviductal pathologies in the buffalo Occurrence, diagnostic and therapeutic approaches. *Asian Pac. J. Reprod.* 3, 156–168.
- Rechsteiner, S.F., Rodrigues, R.F., Cruz, L.A., 2015. Bilateral hydrosalpinx in a mare – a case report. *Arq. Bras. Med. Vet. Zootec.* 67, 723–726.
- Santa Rosa, J., 1996. Sistema Genital, in: *Enfermidades em caprinos: diagnóstico, patologia, terapêutica e controle*, [Genital System, in: Diseases in goats: diagnosis, pathogenesis, therapeutics and control]. Embrapa – SPI, Brasília, pp. 43–83.
- Sattar, A., Khan, M.Z., Siddique, M., 1988. Incidence: pathology and bacteriology of abnormalities of fallopian tubes in Goats. *Pakistan Vet. J.* 8, 14–17.
- Simões, J., Baril, G., Azevedo, J., Mascarenhas, R., 2009. Ovarian Cysts (persistent Follicles) and Ultrasonographic Texture of Uterus in a Nulliparous and a Primiparous Goats. Available in: http://www.veterinaria.com.pt/media/DIR_27001/A-VCP1-2-e1.pdf. ISSN. 1647-3019.
- Souza, J.M.G., Maia, A.L.R.S., Brandão, F.Z., Vilela, C.G., Oba, E., Bruschi, J.H., Fonseca, J.F., 2013. Hormonal treatment of dairy goats affected by hydrometra associated or not with ovarian follicular cyst. *Small Rumin. Res.* 111, 104–109.
- Strandell, A., 2000. The influence of hydrosalpinx on IVF and embryo transfer: a review. *Hum. Reprod. Update* 6, 387–395.
- Wittek, T., Erices, J., Elze, K., 1998. Histology of the endometrium, clinical-chemical parameters of the uterine fluid and blood plasma concentrations of progesterone estradiol 17β and prolactin during hydrometra in goats. *Small Rumin. Res.* 30, 105–112.
- Zhu, L., Chen, J., Sun, Y., Huang, X., Xu, H., Zhang, X., 2013. Loss of nerve fibers in the oviduct isthmus in women with hydrosalpinx. *Acta Histochem.* 115, 609–615.